

Original Article

Anatomical Relationship between the Roots of Erupted Maxillary Posterior Teeth and Maxillary Sinus using CBCT in Sulaimani City (A Retrospective Study)

Mohammed A. Mahmood^{1*}, Tavga M. Faris², Rukhosh H. Abdalrahim¹, Ranj A. Jalal³

Abstract

Objective: Cone beam computed tomography (CBCT) may be recommended as a dose-sparing technique and 3D imaging that provides the clinician more details for examining the maxillary sinus and its relation to the root apices of upper posterior teeth, as compared with standard medical computed tomography.

Methods: A total of (340) CBCT images were examined, images were analyzed by using (Galileos Viewer Software Version 1.9, Dentsply). The distance was measured from the molar and premolar teeth; the closest tooth to the sinus was considered for both sides using the software measuring tool.

Results: A total of 340 CBCTs were examined. One hundred and forty-seven CBCTs were included that matched the criteria. After examination of the CBCTs, the most common relation between the roots of the upper posterior teeth with the maxillary sinus was Type 2: the apices of the upper posterior teeth touching the sinus floor. The result shows no statistical difference between the age groups (p value = 0.135); also, the relationship between sex and the relation of the teeth with the maxillary sinus was not significant (p value = 0.075).

Conclusions: The most common relation between the apices of maxillary posterior teeth and the maxillary sinus was close contact. We also concluded that the use of CBCT is essential in diagnosing the type of relation, especially during procedures where oro-antral communication and trauma to the maxillary sinus is possible.

Keywords: Maxillary sinus, CBCT, Sulaimani city, Anatomy.

Submitted: June 17, 2022, Accepted: March 7, 2023, Published: August 1, 2023.

Cite this article as: Mahmood MA, Faris TM, Abdalrahim RH, Jalal RA. Anatomical Relationship between the Roots of Erupted Maxillary Posterior Teeth and Maxillary Sinus using CBCT in Sulaimani City (A Retrospective Study). Sulaimani Dent J. 2023;10(2):1-7.

DOI: <https://doi.org/10.17656/sdj.10168>

1. Dental Basic Sciences Department, College of Dentistry, University of Sulaimani, Sulaimani, Iraq.
2. Conservative Department, College of Dentistry, University of Sulaimani, Sulaimani, Iraq.
3. Oral Diagnosis Department, College of Dentistry, University of Sulaimani, Sulaimani, Iraq.

* Corresponding author: mohammed.mahmood@univsul.edu.iq.

Introduction

The maxillary sinus is the largest of the four sinuses in the skull, and is located in the body of the maxilla. There are three main processes or projections of the maxilla: the alveolar process, inferiorly (bounded by the alveolar ridge), the zygomatic recess (bounded by the zygomatic bone), and the infraorbital process superiorly (bounded by the bony floor of the orbit, and below it, the canine fossa). The alveolar and palatine processes form the floor of the maxillary sinus. Usually, the maxillary sinus is separated from the roots of the maxillary posterior teeth by a layer of cancellous bone, although occasionally significant bone volume is absent, allowing the apices of the molar teeth to be very near or project into the floor of the sinus cavity. The posterior maxilla has been described as the most difficult and problematic intraoral area¹.

The adult sinus is variable in its extension. In about half of the population, the sinus floor extends between adjacent teeth or individual roots, creating elevations in the nasal surface, commonly known as ‘hillocks’. This anatomical configuration provides a direct pathway for dental infections to spread into the maxillary sinus. In such cases, tooth extraction may cause oro-antral fistula formation, with or without infection¹⁻³. In 11% of all cases, an oro-antral communication is the most common operative complication during extraction of upper wisdom teeth⁴.

Orthopantomography (OPG) images have been used to examine the maxillary sinus, but the sinus has never appeared in detail or in a three dimensional way that makes all the aspects of the sinus visible⁵. Cone beam computed tomography (CBCT) may be recommended as a dose-sparing technique and a 3D image that provides the clinician more details as compared with standard medical computed tomography^{6,7}.

At the edentate stage of life, the size of the maxillary sinus increases further, often filling a large part of the alveolar process, leaving sometimes only a paper-thin bone wall on the lateral and occlusal sides. This process of pneumatization of the sinus varies greatly from person to person and even from side to side⁸. So, the aim of this study was to find the vertical and horizontal relations between the roots of upper maxillary posterior teeth with the inferior border of the maxillary sinus using CBCT, and to find a norm for the Kurdish population regarding the relationship between the roots of maxillary posterior teeth with the maxillary sinus.

Materials and methods

A total of (340) CBCT images were examined, images were analyzed by using the original software from the

manufacturer (GALILEOS Viewer Software Version 1.9, DENTSPLY). The distance was measured from the molar and premolar apices, the closest tooth to the sinus was considered in the measurement and calculated in millimeters.

For evaluating the relationship between maxillary sinus floor and the maxillary teeth apices, the classification implemented in the study by Jung (2009) was used (Figure 1)^{1,9}:

Type 0: The maxillary sinus floor is located above the maxillary posterior root tips.

Type 1: The root apex touches the sinus floor.

Type 2: The maxillary sinus floor is interposed between the roots.

Type 3: Apical protrusion is observed over the maxillary sinus floor.

Horizontal relationship between the teeth of Type 1 and 3 and the maxillary sinus floor was also assessed (Figures 2 and 3).

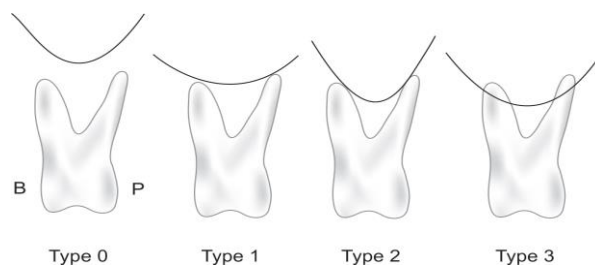


Figure 1: The vertical relationship of the roots of maxillary and the premolars with the maxillary floor of the sinus (B: buccal; P, palatal).

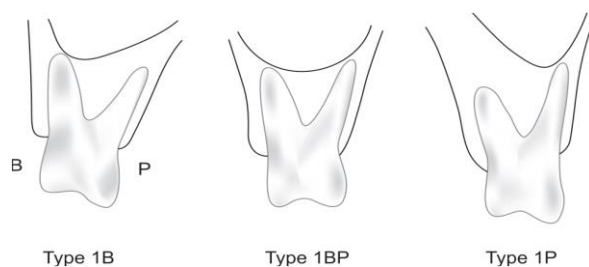


Figure 2: Classifications of how the root apex touches the sinus floor (B: buccal; P: palatal). Type 1B: The buccal roots touch the sinus floor; Type 1BP: the buccal and palatal roots touch the floor of the sinus; Type 1P: The palatal root touches the floor of the sinus.

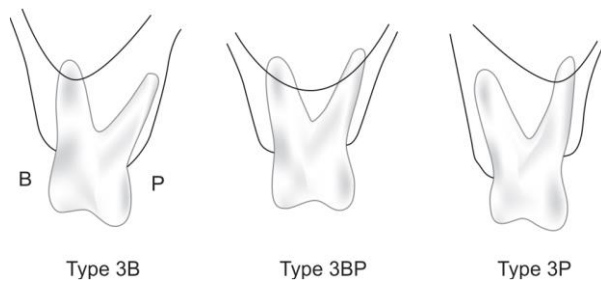


Figure 3: Three classifications of apical protrusion (B: buccal; P: palatal). Type 3B: The buccal roots project into the sinus cavity; Type 3BP: The buccal and palatal roots project into the sinus cavity; Type 3P: The palatal root projects into the sinus cavity.

The inclusion criteria¹⁰

1. The age of the objects should be greater than 21, for the full development of the maxillary sinus.
2. No history of orthodontic treatment, as this may affect the natural position of the teeth.
3. No history of sinus surgeries, as this may alter the morphology of the sinus.
4. No history of posterior teeth periapical surgery, as this may affect the amount of bone adjacent to the sinus.
5. No missing teeth at the level of the sinus, as this may lead to inclination of the teeth.
6. No dental implant at the area adjacent to the sinus.
7. No extraction or prosthesis in the opposite teeth to the upper posterior teeth as this may predispose to over eruption.

The (GALILEOS Viewer) computer software program was used, the measuring tool inside the program was used to measure the distance between the maxillary sinus and the apices of the examined teeth.

The images were reworked according to the panoramic view (to adjust the view), axial plane (to assess the relation of roots with the maxillary sinus, and tangential "lateral" plane (to confirm the reading of the axial view). The computer mouse cursor was scrolled in the coronal apical direction to adjust the views.

Ethical approval was obtained on December 13, 2021 and registered with the scientific committee under the number (444).

Statistical analysis

All patients' data were analyzed by statistical software package SPSS 26 (SPSS Inc., Chicago, IL, USA) The distribution of the sample according to age and sex was arranged in tables, and the sample was tested for normality after calculation of standardized residuals, using Shapiro-wilk (W) goodness-of-fit test. Accordingly Kruskal-Wallis H test and Mann-Whitney U test were used to calculate the differences among age groups and sexes.

Results

A total of 340 CBCTs were examined, of which 193 were excluded as they did not match the criteria mentioned in the method section. One hundred and forty-seven CBCTs were included that matched the criteria: 64 males (43.5%) and 83 females (56.5%). Some exclusions were due to the presence of unilateral reasons for exclusion, such as missing teeth in one side.

For calculation of the data, standardized residuals were calculated and tested for normality using Shapiro-wilk (W) goodness-of-fit test, the test showing significant deviation from normality (p-value=0.000).

After examination of the CBCTs, the most common relation between the roots of the upper posterior teeth with the maxillary sinus was Type 2 (apices of the upper posterior teeth touching the sinus floor): 84 cases (57.1%) for the right side and 77 cases (52.4%) for the left side. The distributions of the relations of all types found in this study are summarized in (Table 1) (Figure 4).

Regarding the differences between age groups, Kruskal-Wallis test identified no significant differences between the age groups (p-value= 0.135) (Table 2).

Mann-Whitney U test was used to show the differences between males and females, and the test results identified no significant differences (p-value 0.075) (Table 3).

Table 1: Frequency distribution of the sample regarding both sides.

		Frequency	Percent
Right	Excluded	11	7.5%
	Away	14	9.5%
	Touch	84	57.1%
	Between	6	4.1%
	Penetrate	32	21.8%
Left	Excluded	15	10.2%
	Away	15	10.2%
	Touch	77	52.4%
	Between	2	1.4%
	Penetrate	38	25.9%

Table 2: Kruskal-Wallis H test, comparing Age groups for both sides.

	Ranks			Kruskal-Wallis H
	AgeGroups	N	Mean Rank	
Right Group	21-30	44	80.90	p-value= 0.135
	31-40	48	71.51	
	41-50	36	71.88	
	51-60	13	77.23	
	61-70	5	45.40	
	More than 70	1	67.50	
	Total	147		
Left Group	21-30	44	84.69	
	31-40	48	68.33	
	41-50	36	71.29	
	51-60	13	59.50	
	61-70	5	80.60	
	More than 70	1	128.50	
	Total	147		

Table 3: Difference between males and females using Mann-Whitney U test.

	Sex	N	Mean Rank	Sum of Ranks	Mann-Whitney U
RightGroup	Male	64	77.45	4956.50	p-value= 0.075
	Female	83	71.34	5921.50	
	Total	147			
LeftGroup	Male	64	80.51	5152.50	
	Female	83	68.98	5725.50	
	Total	147			

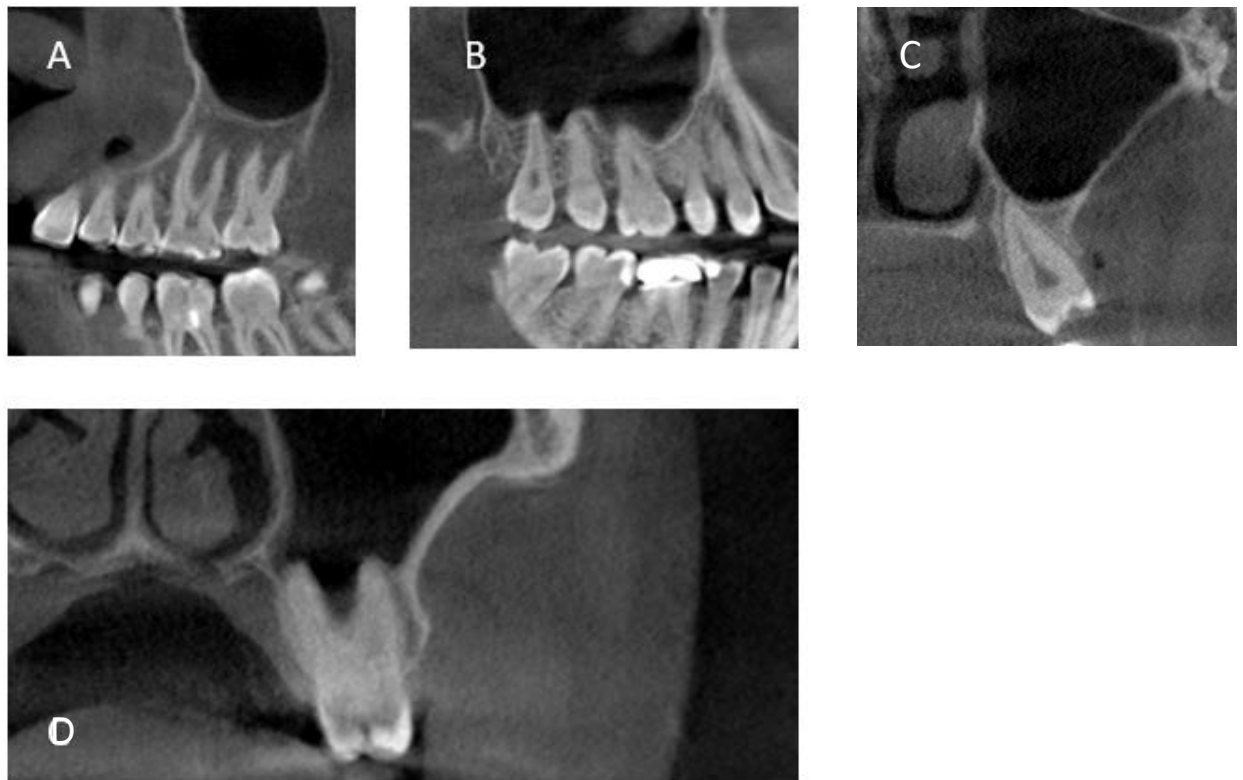


Figure 4: Types of relations found in this study, A: Away, B: Between the roots, C: Touching the sinus, D: Penetrating the sinus.

Discussion

The tool used in this study was CBCT which exposes the patient to low radiation and provides a three-dimensional visualization of the head region^{6,7}.

The result shows that the most common relation between the upper maxillary teeth and the maxillary sinus was Type 2: in contact or touching. This relation should be considered by the clinicians as it is not free from risk of injury to the maxillary sinus floor. A study done by James A. Wallace JA (1996) reported that the sinus may extend to crest of the ridge; hence, the anatomical location and variation of the sinus make the use of CBCT of great importance¹⁰.

Other studies³ have, like this study, reported close and intimate contact of roots of the maxillary posterior teeth with the floor of maxillary sinus.

It is important to consider the potential influence of ethnic factors when interpreting the results of this study in terms of the relationship between the roots of posterior teeth and the maxillary sinus. Two studies, conducted in Iran and India^{11,12}, found that the most common relationship was type (0) where there is no proximity. Another study, conducted in South Korea¹³, concluded that the most common relationship is type (3). This diversity in results can be explained by the effect of the ethnic factor, as it may affect the shape of the face and size of the jaw, and subsequently the position of the maxillary sinus.

The relationship between posterior maxillary teeth and the maxillary sinus floor is important to consider during dental treatments, particularly root canal treatments, to avoid potential risks associated with the penetration of teeth root tips into the maxillary sinus^{4,14}.

Type 2 cases are those where the maxillary sinus touches the roots of the posterior maxillary teeth, which increases the risk of complications during dental treatments such as surgeries and root canal treatment. In such cases, care must be taken to avoid perforating the sinus floor or apical tissues during the treatment. Perforation of the maxillary sinus can lead to serious complications, such as sinusitis, abscess formation, and even orbital abscess, as reported in the case of a maxillary first molar root canal treatment. Rapid exacerbation of periapical inflammation can occur due to the penetration of infected material into the sinus, leading to complications that require urgent medical attention¹⁵.

Therefore, assessing the relationship between posterior maxillary teeth and the maxillary sinus floor is critical to prevent such complications. This can be achieved through using cone-beam computed tomography (CBCT) and other diagnostic tools to accurately identify the position of the sinus relative to the roots of the teeth. Careful treatment planning and execution are essential to avoid potential complications and ensure the best possible outcomes for the patient¹⁶.

Size of the database was a limitation of this study as it was difficult to collect CBCT images from all radiology centers. Another limitation related to finding the norm for the Kurdish population, which is a secondary outcome of this study, and a larger and broader database is crucial to make the finding more representative of the Kurdish population.

Awareness of the anatomy of the region is essential for the clinicians to deal with this challenging anatomical area¹². Ultimately, the hope is that this research will lead to improved outcomes for patients and better overall healthcare delivery.

Conclusion

The most common relation between the apices of maxillary posterior teeth and the maxillary sinus was close contact. We also concluded that the use of CBCT

is essential in diagnosing the type of relation, especially during implant placement, endodontic treatment, endodontic surgeries, and surgical tooth extraction where oro-antral communication is possible. This recommendation for using CBCT is a reflection of its anatomical variations regarding the size and position of the sinus in relation to the teeth and the crest of the bone.

References

1. Kao DW. Clinical Maxillary Sinus Elevation Surgery: Wiley Online Library; 2014.
2. Sánchez-Pérez A, Boracchia AC, López-Jornet P, Boix-García P. Characterization of the Maxillary Sinus Using Cone Beam Computed Tomography. A Retrospective Radiographic Study. *Implant Dent*. 2016;25(6):762-9.
3. Kilic C, Kamburoglu K, Yuksel SP, Ozen T. An Assessment of the Relationship between the Maxillary Sinus Floor and the Maxillary Posterior Teeth Root Tips Using Dental Cone-beam Computerized Tomography. *Eur J Dent*. 2010;4(4):462-7.
4. Rothamel D, Wahl G, d'Hoedt B, Nentwig GH, Schwarz F, Becker J. Incidence and predictive factors for perforation of the maxillary antrum in operations to remove upper wisdom teeth: prospective multicentre study. *Br J Oral Maxillofac Surg*. 2007;45(5):387-91.
5. Ohba T, Katayama H. Panoramic roentgen anatomy of the maxillary sinus. *Oral Surg Oral Med Oral Pathol*. 1975;39(4):658-64.
6. Ilgüy D, Ilgüy M, Dolekoglu S, Fisekcioglu E. Evaluation of the posterior superior alveolar artery and the maxillary sinus with CBCT. *Braz Oral Res*. 2013;27(5):431-7.
7. Plotino G, Tocci L, Grande NM, Testarelli L, Messineo D, Ciotti M, et al. Symmetry of root and root canal morphology of maxillary and mandibular molars in a white population: a cone-beam computed tomography study in vivo. *J Endod*. 2013;39(12):1545-8.
8. Orhan K, Kusakci Seker B, Aksoy S, Bayindir H, Berberoğlu A, Seker E. Cone beam CT evaluation of maxillary sinus septa prevalence, height, location and morphology in children and an adult population. *Med Princ Pract*. 2013;22(1):47-53.
9. Jung Y-H, Cho B-H. Comparison of panoramic radiography and cone beam computed tomography for assessing the relationship between the maxillary sinus floor and maxillary molars. *Imaging Science in Dentistry*. 2009;39(2):69-73.
10. Wallace JA. Transantral endodontic surgery. *Oral Surg Oral Med Oral Pathol Oral Radiol Endod*. 1996;82(1):80-3.
11. Shokri A, Lari S, Yousef F, Hashemi L. Assessment of the relationship between the maxillary sinus floor and maxillary posterior teeth roots using cone beam computed tomography. *J Contemp Dent Pract*. 2014;15(5):618-22.

12. Kantarci M, Karasen RM, Alper F, Onbas O, Okur A, Karaman A. Remarkable anatomic variations in paranasal sinus region and their clinical importance. *Eur J Radiol.* 2004;50(3):296-302.
13. Jung YH, Cho BH. Assessment of the relationship between the maxillary molars and adjacent structures using cone beam computed tomography. *Imaging Sci Dentistry.* 2012;42(4):219-24.
14. Koch F, Breil P, Marroquin BB, Gawehn J, Kunkel M. Abscess of the orbit arising 48 h after root canal treatment of a maxillary first molar. *Intl Endod J.* 2006;39(8):657-64.
15. Oberli K, Bornstein MM, von Arx T. Periapical surgery and the maxillary sinus: radiographic parameters for clinical outcome. *Oral Surgery, Oral Medicine, Oral Pathology, Oral Radiology, and Endodontology.* 2007;103(6):848-53.
16. Fry RR, Patidar DC, Goyal S, Malhotra A. Proximity of maxillary posterior teeth roots to maxillary sinus and adjacent structures using Denta scan®. *Ind J Dent.* 2016;7(3):126-30.