

Original Article

# Marsupialization as an Organ Preservation Measure in Management of Odontogenic Cyst

Rozhan N. Saeed<sup>1</sup> , Suha N. Aloosi<sup>1\*</sup> 

## Abstract

**Objective:** Odontogenic cysts are a category of intra-osseous lesions that occur frequently. Marsupialization can be the main therapeutic option for patients with large cysts or lesions to preserve crucial anatomical structures. The goal of this study was to treat individuals with odontogenic cystic lesions conservatively using the marsupialization method.

**Methods:** Twenty-two patients participated in this research as part of a cross-sectional study designed for statistical purposes. The study included males and females between the ages of 6 and 80 with biopsy-proven odontogenic cysts.

**Results:** After the treatment of 22 patients, data were collected and analyzed statistically. The statistical analysis was performed with the use of Microsoft Excel and SPSS (Statistical Package for the Social Sciences). The Spearman coefficient was used to evaluate the correlation between patient age and marsupialization duration and the correlation between cyst size and marsupialization duration, while the Kruskal-Wallis test was used to illustrate the link between cyst type and marsupialization duration. Moreover, the Mann-Whitney U test was used to assess statistical variations between variables.

**Conclusions:** Marsupialization is a conservative, noninvasive procedure that is effective in reducing the cyst's size until it is fully resolved or reaches a certain point suitable for excision by enucleation. The marsupialization treatment was also advantageous in preserving teeth, bones, the inferior alveolar nerve, the maxillary sinus, and the nasal cavity. The main purpose of this study was to preserve the vital structures that were compromised by the different types of odontogenic cysts, and the treatment strategy successfully achieved that goal.

**Keywords:** *Inferior Alveolar Nerve (IAN), Keratocyst, Marsupialization, Odontogenic cysts, Organ preservation.*

*Submitted: July 25, 2022, Accepted: January 21, 2023, Published: August 1, 2023.*

**Cite this article as:** Saeed RN, Aloosi SN. Marsupialization as an Organ Preservation Measure in Management of Odontogenic Cyst. *Sulaimani Dent J.* 2023;10(2):19-26.

**DOI:** <https://doi.org/10.17656/sdj.10170>

1. Oral and Maxillofacial Surgery Department, College of Dentistry, University of Sulaimani, Sulaimani, Iraq.

\* Corresponding author: [suha.hussein@univsul.edu.iq](mailto:suha.hussein@univsul.edu.iq).

## Introduction

Odontogenic cysts are epithelial-lined pathological cavities that are lined by epithelium derived from the odontogenic epithelium<sup>1</sup>. It is believed that they are the product of inflammatory or developmental pathogenic factors; odontogenic cysts may originate from the reduced enamel epithelium of a tooth crown, epithelial rests of Malassez, or remnants of the dental lamina<sup>2</sup>. Harris mentioned that odontogenic cysts' growth occurs as the surrounding bone resorbs and intra-cystic contents accumulate, which may include cyst epithelium and plasma proteins; as a result of the increase in the size of Odontogenic cysts, bone destruction will subsequently occur<sup>3,4</sup>.

Different treatment approaches have been described; a treatment strategy is chosen according to the cyst size and the relationship between the cyst and the surrounding tissues and adjacent teeth<sup>5</sup>. It is possible to remove the cyst through enucleation (complete excision of the cyst) and wait for spontaneous bone regeneration to occur<sup>6</sup>. Cysts are removed by enucleation when they are small in size, and the affected tooth cannot be saved<sup>7</sup>. Other surgical options, like osteotomy (removal of the peripheral bone) or en-bloc resection of the cyst and the bone around it, have also been suggested<sup>8</sup>.

Partsch described the first-time marsupialization as a therapy for cystic lesions<sup>9</sup>. Marsupialization of cysts is a process that relies on the partial removal of the cyst lining. It is possible to invaginate the oral cavity or maxillary antrum by opening the cyst and emptying it. This technique maintains continuity between the oral cavity and the cyst<sup>10</sup>. Mostly because of marsupialization and decompression, key anatomical features such as the inferior alveolar nerve can be preserved without risking deformity<sup>11</sup>.

## Materials and methods

A cross-sectional study was conducted in Sulaymaniyah governorate, in which twenty-two patients were enrolled to analyze their treatment methods. Patients with various odontogenic cystic lesions, both male and female, between the ages of 6 and 80 years old, were included in the study. They all had odontogenic cysts, which required surgical intervention. The treatment took place at different medical facilities, such as the Sulaymaniyah Teaching Hospital and the Faculty of Dentistry at Sulaymaniyah University. The duration of the treatment was about 16 months.

The inclusion criteria for this research included patients in different age groups and with different types of odontogenic cystic lesions that involved one of the jaws (either lower or upper) and cysts affecting vital structures, while the exclusion criteria were pretreated cysts, odontogenic cysts associated with malignancy, or with a pathological fracture.

The diagnosis was carried out by acquiring the patient's medical history and performing a clinical and radiological examination by cone beam computed tomography (CBCT) to evaluate the actual size of the cyst (which was measured by the greatest diameter of the cyst in millimeters) and its severity. The diagnosis was confirmed by incisional biopsy collection, which was made during marsupialization. Consent forms were obtained from the patients before surgery.

The treatment plan for the patients included surgical interference (marsupialization). Each patient was treated by selecting the marsupialization approach, among the other modalities of cyst treatments such as enucleation and jaw resection. A histopathological evaluation was conducted to determine the type of cyst during the marsupialization.

The process of the marsupialization technique included patient preparation for general or local anesthesia. A prophylactic antibiotic was given to the selected patients. Marsupialization was performed by creating a surgical window in the cyst wall in a place where the buccal plate was affected by the cyst, keeping the lower part of the mucosa attached wherever possible. The surgical window should be suitable for the frequent changing of the pack and, at the same time, approachable for cleaning, but not conspicuous for the patients.

Following the evacuation of the cyst's contents, fragments of the cyst's epithelial linings were also removed and sent for histopathological investigation. The oral epithelium was turned back inside the cyst and sutured to the epithelial lining of the cyst, as shown in Figure 1.

The cyst was evacuated and thoroughly washed with normal saline solution, then packed with an Iodoform pack. The pack was changed weekly (up to ten days), removed, and then the cavity was washed and irrigated with normal saline solution, then packed again with the iodoform gauze. The iodoform gauze can be soaked with an antibiotic ointment such as tetracycline. The patient was instructed to follow good oral hygiene measures using chlorhexidine, mouthwash and analgesia, and the patient was sent home until the next appointment. This process is shown in Figure 1.

To evaluate the change in the size of the cystic lesions and the complete clinical healing of the lesions, essential radiological investigations such as cone beam computed tomography (CBCT) along with histopathological investigations were sometimes carried out to evaluate the marsupialization process, as shown in Figure 2.

The process was to be completed by the cavity healing, which was evaluated by the complete filling of the cavity with mature and immature bone along with some fibrous tissue until there was no space in which to insert the pack (first end point) or when the complete surgical excision of the cyst was to be performed (second end point), which would be when the CBCT proved that at least 2-3 mm of bone was formed around the vital structures that were originally affected by the cyst, such as the inferior alveolar nerve, palatal plate, teeth (erupted and unerupted), lingual and buccal plates, and maxillary sinus. The surgical excision of the cyst would then be possible, guaranteeing the preservation of these vital organs that were at risk. Again, all the specimens were to be examined histopathologically.

### Statistical analysis

The statistical analysis was performed using Excel and SPSS. The statistical test known as the Spearman coefficient was used to assess the statistical association between the patient's age and the duration of the marsupialization as well as the correlation between cyst size and duration, while the Kruskal-Wallis test was applied to demonstrate the correlation between cyst type and duration of marsupialization. The Mann-Whitney U test was additionally used to assess statistical differences among variables.

### Results

Following treatment of all 22 individuals, data were collected and statistically assessed. Every patient had complete marsupialization as a part of their therapy for various periods of time. Enucleation was performed following discussion with the patient, and radiological imaging revealed at least 2–3 mm of bone had formed between the structure at risk and the jaw cyst. Only three patients were totally healed by marsupialization alone; 18 needed surgical interference.

Among the sample were 22 patients (13 males and 9 females with a mean age of 37.59), ranging in age from 4 to 73 years. There were eleven people affected by keratocysts: six by dentigerous cysts; three by incisive cysts; one by traumatic cyst, and one by radicular cyst. Marsupialization lasted from 90 to 480 days, or around three to sixteen months.

### Study variables

The variables for this research were documented and analyzed using various statistical tests; these variables

included the gender of the patient, age of the patient, type of the cyst, location of the cyst, vital structures that were at risk, duration of marsupialization, which was calculated in days, and size of the cyst, which was measured in millimeters, as shown in Table 1.

Table 1 shows the information regarding the patients administered for odontogenic cyst diagnosis and treatment. Twenty-two individuals were included in this study. Gender analysis showed the greater frequency of the incident in males compared to females, with nine female patients (40.9%) and thirteen male patients (59.1%) in the total sample. The mean age was about 37.59 years old, with the youngest patient being four years old and the eldest being 73 years old. There were 11 cases with OKC type. All 22 cases were analyzed; 63.6% of the odontogenic cysts were located in the mandible, and about 36.4% were located in the maxilla. The average duration of marsupialization was about 171 days, and the mean size of the cyst was 51.41 mm.

Table 2 shows Spearman's rho correlation coefficient between age and size with duration of marsupialization. In this research, the duration of marsupialization ranged between 90 and 480 days, or about 3 and 16 months. The Spearman coefficient statistical test was used to represent the statistical correlation between the duration of marsupialization and the patient's age, which was equal to (0.524) with a p-value of 0.012, which means that there was a significant intermediate correlation between age and duration of marsupialization. Spearman's correlation coefficient also showed that the correlation between the duration of marsupialization and the size of odontogenic cyst was highly significant and equal to (0.675) with a (p-value =0.001).

Table 3 shows the distribution between the duration of marsupialization, calculated in days, and the type of odontogenic cyst, location of the cyst, and gender. The Kruskal-Wallis Test showed that the duration of marsupialization, which was measured in days, was the same across all the types of odontogenic cysts. As a result, the null hypothesis that there was no significant difference between the treatment duration and the type of odontogenic cyst (P-value = 0.118) was retained. The Mann-Whitney U test was used to determine whether the cyst's location was related to the duration of marsupialization. The statistical test showed that the location of the cyst (mandible or maxilla) required approximately the same duration of treatment as if the p-value was greater than 0.05. The Mann-Whitney U test was also used to determine if the gender of the patient had an effect on the duration of marsupialization;

the statistical test revealed that both genders (male and female) required approximately the same duration of treatment, and the p-value was greater than 0.05.

In this study, the most vital structures that were compromised by the odontogenic cyst were the inferior

alveolar nerve (IAN), with a percentage of 30.43%, followed by the palatal plate at about 21.74%, followed by the teeth at about 13.04%, followed by the lingual plate at about 10.87%, followed by the nasal cavity at about 8.70%, followed by the buccal plate and the maxillary sinus at about 6.52% equally, and finally the least vital structure affected was the labial plate, at about 2.17%, as shown in Figure 3.

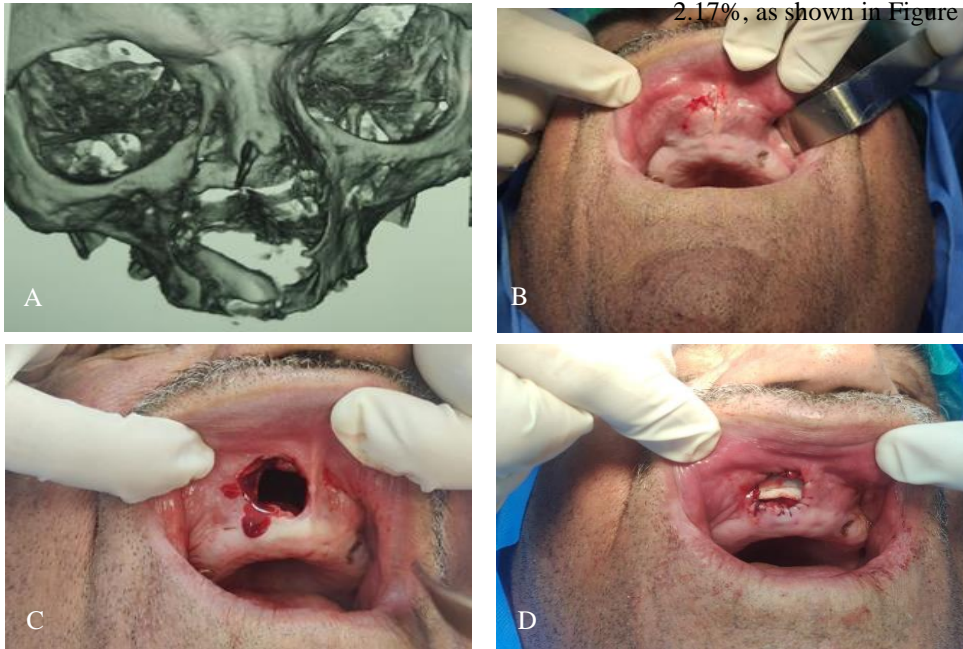


Figure 1: A: Cone beam computed tomography (CBCT) of the maxilla of patient number 17, shows a dentigerous cyst causing bone resorption in the nasal floor, labial plate, and palatal plate associated with an impacted canine. An intraoperative photograph shows bulging of the cyst in the labial area of the maxilla. C: Shows removal of a portion of the cyst's epithelium and evacuation of the cyst's contents. D: Shows suturing and insertion of an iodoform pack.

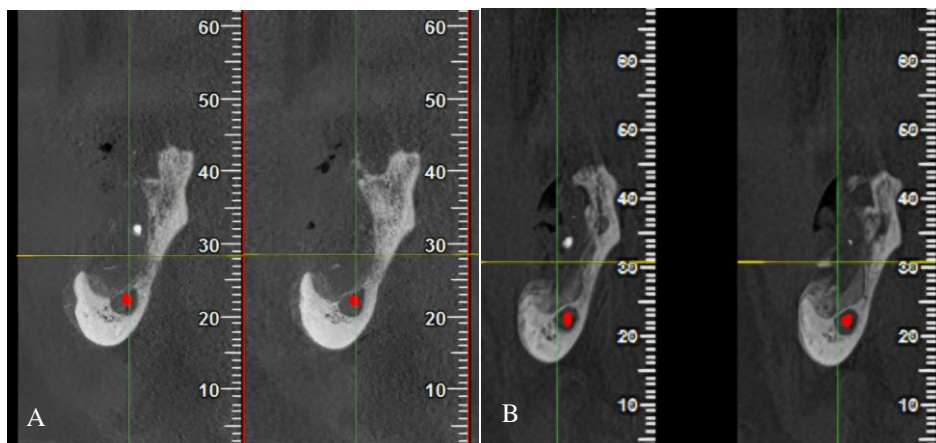


Figure 2: Cross-sectional view of cone beam computed tomography (CBCT) for the right side of the body of mandible of patient number 11, who was presented with a cystic lesion that was proved to be odontogenic keratocyst (OKC) by the histopathological examination, a: before the Marsupialization procedure, b: after seven months of marsupialization, the bone formation around the inferior alveolar nerve can be noticed.

Table 1: Descriptive statistics.

Variables	N(%) or Mean (S.D.)
Gender-male(%)	13(59.1)
Age in years (SD)	37.59(18.82)
Type of the cyst-OKC(%)	11(50)
Location of the cyst -mandible(%)	14(63.6)
Vial structures at risk-IAN(%)	8(36.4)
Duration of marsupialization (SD)	171(97.83)
Size of the cyst (SD)	51.41(30.53)

Table 2: Spearman's rho correlation coefficient between age and size with duration of marsupialization.

		Duration of Marsupialization (Days)
Age	Correlation Coefficient	0.524*
	P-value	0.012
Size (greatest diameter)	Correlation Coefficient	0.675*
	P-value	0.001

\*: Correlation is significant at the 0.05 level

Table 3: Shows the distribution between the duration of marsupialization calculated in days, the type of odontogenic cyst, location of the cyst, and gender.

Variables	Class	Duration of Marsupialization (Days)			Test	P-Value
		Count	Mean	SD		
Type of the cyst	Dentigerous	6	147.5	54.841	7.351 <sup>a</sup>	0.118
	Incisive	3	105	0		
	OKC	11	212.73	119.778		
	Radicular	1	120	-		
	Traumatic	1	105	-		
Location of the cyst	Mandible	14	185.36	115.982	46 <sup>b</sup>	0.487
	Maxilla	8	146.25	51.182		
Gender	Male	13	195	119.06	51 <sup>b</sup>	0.61
	Female	9	136.67	40		

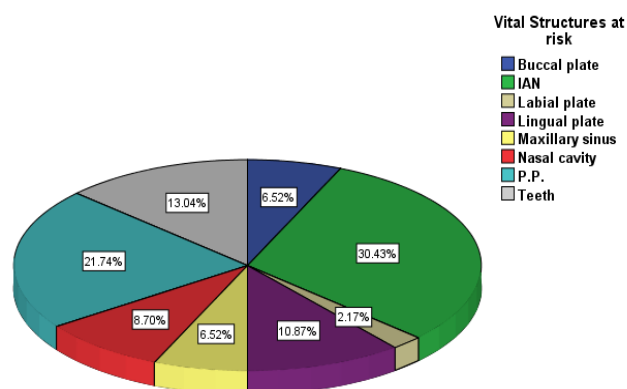


Figure 3: pie chart shows the percentage of the vital structures at risk.

## Discussion

Organ preservation has played a significant role in procedures that involve the face and neck, as jaw cysts can induce bone loss and the resorption or displacement of nearby teeth. This research aimed to preserve the crucial anatomical structures. In order to preserve these vital structures associated with these cystic lesions, the marsupialization procedure was suggested as a conservative treatment modality. It was performed for the presented odontogenic cystic lesions in individuals included in this study. Recent years have seen an increase in studies citing marsupialization as a promising method for treating jaw cystic lesions<sup>12-13</sup>.

This research included marsupialization for various types of odontogenic cysts; 50% of the sample patients had keratocysts; dentigerous cysts were observed in 27.27% of the patients that received marsupialization; almost 13.64% of the patients were treated for incisive cysts; and 4.55% of the patients had radicular and traumatic cysts.

The patient's age, the size, and the type of the cyst were all factors that played a role in the treatment outcome; for example, the results of our research showed that the age of the patient plays a role in terms of the duration of marsupialization, as the duration of marsupialization was significant at about ( $p$ -value = 0.012). Some studies indicate that age has an impact on bone healing after jaw cyst therapy<sup>14-15</sup>. On the other hand, several researchers claim that aging does not significantly affect bone repair<sup>16-18</sup>.

Regarding the duration of Marsupialization and its association with the size of the odontogenic cyst, this research's results showed that the duration of the marsupialization was correlated to the size of the odontogenic cyst (the greatest diameter represented the

size) ( $p$ -value=0.001), the treatment duration ranged from (90-480) days, the longest duration lasted 480 days while the shortest was 90 days. Kubota et al. found that the speed of the shrinking process of the odontogenic cyst was correlated to the original size of the cyst, which indicated that the larger the lesions, the faster the healing process<sup>18</sup>.

Based on data recovered from this research, many vital organs were affected by different types of odontogenic cysts. Marsupialization is the preferred treatment to preserve vital structures such as nerves, sinuses, and teeth, as well as to prevent bone deformities and neurovascular injury. Other studies have reported on choosing the marsupialization procedure for the preserving of these vital organs<sup>19-20</sup>.

In this study, the most common organ that faced complications and risks was the inferior alveolar nerve (IAN), which was impacted in 30.43% of the overall cases of lower jaw cysts. The procedure of marsupialization preserved the inferior alveolar nerve (IAN) and resulted in bone formation around the inferior alveolar canal (IAC). Hence, when about 2 mm or more of bone genesis was observed radiologically around the inferior alveolar nerve (IAN) or the other structures at risk, the surgeon decided it was safe enough to perform complete enucleation of the cyst without jeopardizing the inferior alveolar nerve (IAN). As a result, enucleation can only be performed safely if enough bone has been formed. Existing studies assessing bone healing following marsupialization have, however, been reported very infrequently<sup>21-22</sup>.

The other major structures affected by the odontogenic cyst were the maxillary sinuses, about 6.52%. By performing marsupialization for patients affected by the odontogenic cysts, the sinuses were well preserved. Other studies have also shown that marsupialization aids in sinus preservation<sup>23-25</sup>. Jaw cysts can induce the resorption or displacement of nearby teeth. The teeth were affected by a percentage of 13.04%. In this research, marsupialization assisted in maintaining the teeth affected by the odontogenic cysts. Other studies have proven this perspective, particularly in pediatric patients whose dentition was highly affected by the odontogenic cysts<sup>26-27</sup>.

Jaw cysts can induce bone resorption and facial deformity, as mentioned by Meningaud et al.<sup>28</sup>

In our research, the affected palatal, lingual and labial bone plates were affected by different percentages (21.74 %, 10.87%, 2.17%). Other researchers have reported that marsupialization was the ultimate treatment option in order to preserve jaw bones<sup>29,30</sup>.

In terms of the types of odontogenic cysts and the period of marsupialization, the research revealed that the duration of the marsupialization was the same across all the types of odontogenic cysts; thus, the null hypothesis that there is no significant difference in the treatment duration and the type of the odontogenic cyst ( $p$ -value = 0.118) is retained. However, the OKC appeared to be more responsive to marsupialization than other types of odontogenic cysts. Patients with KCOTs who underwent marsupialization surgery were less likely to have complications. In addition, marsupialization can have a significant impact on the patient's symptoms and quality of life<sup>13-31</sup>. The dentigerous cyst response was about 27.27%. Other studies have reported that marsupialization is not frequently suggested for radicular cysts. However, in this study, marsupialization was recommended in 16 patients because enucleation would have affected the stability of teeth and might have caused a perforation in one of the bone plates. In such cases, marsupialization or decompression can be used as a treatment option, as suggested by other researchers<sup>32</sup>.

The decompression method reduces the lesion to the point where surgical intervention is either unnecessary or limited to the immediate periradicular tissues of the affected teeth. The technique compromises the integrity of the lesion wall, removes the internal differential osmotic pressure, and encourages osseous regeneration for healing, as reported by some researchers<sup>33-34</sup>.

In the current study, treatment was successful in all cases. All cases necessitated surgery after a period of marsupialization; only 3 cases healed completely by marsupialization alone.

Marsupialization is a treatment that holds great results, but no treatment is without its drawbacks and complications. One of the main disadvantages of marsupialization is the long treatment period. It is a lengthy procedure that requires a good follow-up for the patient, and it is the type of procedure that requires a cooperative patient who will irrigate the cavity and keep it clean. Another disadvantage is that some tissue may be left in situ. The advantage of marsupialization is that it preserves the anatomical structures related to odontogenic cysts. In our research, marsupialization surgery was performed on several patients through a surgical window that we created in the cyst wall, which allowed the cyst's contents to be evacuated while also keeping the oral cavity and cyst connected. The cyst's epithelial lining was removed for histopathological examination. According to the cases we took on in this research, treating odontogenic cysts by marsupialization

was successful in terms of preserving the integrity of the vital structures that were at risk.

## Conclusion

Marsupialization is a conservative, noninvasive procedure that is effective in reducing the cyst's size until it is fully resolved or reaches a certain point suitable for excision by enucleation. The main purpose of this study was to preserve the vital structures that were compromised by the different types of odontogenic cysts, and the treatment strategy successfully achieved that goal. The period of marsupialization was significantly correlated to the size of the cyst ( $p$ -value = 0.001) but less significantly to the age of the patient ( $p$ -value = 0.012). We recommend this approach for the management of cysts in the jaw. However, in some cases, the marsupialization process must be prolonged for more successful results regarding the preservation of the inferior alveolar nerve before definitive surgical excision, especially in keratocysts and dentigerous types of cysts. Certain limiting factors influenced the results obtained from this research, including the small sample population to which marsupialization was applied. Further research and investigative studies are recommended for further analysis on this topic.

## References

1. Neville BW, Al E. Oral and maxillofacial pathology. 4th ed. St. Louis: Missouri; 2016.
2. Rajendra Santosh AB. Odontogenic cysts. Dent Clin North Am. 2020;64(1):105-19.
3. Mortha N, Uppala D. Pathogenesis of odontogenic cysts. Oral Maxillofac Surg. 2021;12(1):31.
4. Ochsenius G, Escobar E, Godoy L, Peñafiel C. Odontogenic cysts: analysis of 2,944 cases in Chile. Med Oral Patol Oral Cir Bucal. 2007;12(2):85-91.
5. Yun SU, Jung HW, Cho BY, Choi BJ, Lee BS, Kwon YD, et al. Conservative treatment using marsupialization for cysts occurring in the jaw of adolescents: a case report. J Korean Dent Sci. 2014;7(1):31-7.
6. Buchbender M, Neukam FW, Lutz R, Schmitt CM. Treatment of enucleated odontogenic jaw cysts: a systematic review. Oral Surg Oral Med Oral Radiol. 2018;125(5):399-406.
7. Ghandour L, Bahmad HF, Bou-Assi S. Conservative treatment of dentigerous cyst by marsupialization in a young female patient: a case report and review of the literature. Case Rep Dent. 2018;2018:1-6.
8. Ghali GE, Connor MS. Surgical management of the odontogenic keratocyst. Oral and Maxillofacial Surgery Clinics. 2003;15(3):383-92.

9. De Moraes AT, Soares HA, Pinheiro JD, Ribeiro AL. Marsupialization before enucleation as a treatment strategy for a large calcifying odontogenic cyst: Case report. *Int J Surg Case Rep.* 2020;67(1):239-44.
10. Emam HA, Smith J, Briody A, Jatana CA. Tube decompression for staged treatment of a calcifying odontogenic cyst—a case report. *JOMS.* 2017;75(9):1915-20.
11. Wushou A, Zhao YJ, Shao ZM. Marsupialization is the optimal treatment approach for keratocystic odontogenic tumour. *J Craniomaxillofac Surg.* 2014;42(7):1540-4.
12. Lee ML, Prepageran N, Subha ST. Dentigerous cyst of the maxillary sinus in a child. *Med J Malaysia.* 2004;59(4):550-1.
13. Pogrel MA, Jordan RC. Marsupialization as a definitive treatment for the odontogenic keratocyst. *J Oral Maxillofac Surg.* 2004;62(6):651-5.
14. Gao L, Wang XL, Li SM, Liu CY, Chen C, Li JW, et al. Decompression as a treatment for odontogenic cystic lesions of the jaw. *J Oral Maxillofac Surg.* 2014;72(2):327-33.
15. Anavi Y, Gal G, Miron H, Calderon S, Allon DM. Decompression of odontogenic cystic lesions: clinical long-term study of 73 cases. *Oral Surg Oral Med Oral Pathol Oral Radiol.* 2011;112(2):164-9.
16. Oliveros-Lopez L, Fernandez-Olavarria A, Torres-Lagares D, Serrera-Figallo MA, Castillo-Oyagüe R, Segura-Egea JJ, et al. Reduction rate by decompression as a treatment of odontogenic cysts. *Med Oral Patol Oral Cir Bucal.* 2017;22(5):e643.
17. Lizio G, Sterrantino AF, Ragazzini S, Marchetti C. Volume reduction of cystic lesions after surgical decompression: a computerised three-dimensional computed tomographic evaluation. *Clin Oral Investig.* 2013;17(7):1701-8.
18. Kubota Y, Imajo I, Itonaga R, Takenoshita Y. Effects of the patient's age and the size of the primary lesion on the speed of shrinkage after marsupialisation of keratocystic odontogenic tumours, dentigerous cysts, and radicular cysts. *Br J Oral Maxillofac Surg.* 2013;51(4):358-62.
19. Madras J, Lapointe H. Keratocystic odontogenic tumour: reclassification of the odontogenic keratocyst from cyst to tumour. *J Can Dent Assoc.* 2008;74(2):165-165h.
20. Demir E, Günhan Ö. Treatment results of dentigerous cysts managed by marsupialisation, enucleation or enucleation with platelet rich plasma—a retrospective study. *Meandros med. dental j.* 2021;22(2):116.
21. Bodner L, Bar-Ziv J. Characteristics of bone formation following marsupialization of jaw cysts. *Dentomaxillofac Radiol.* 1998;27(3):166-71.
22. Lizio G, Ferraioli L, Melini M, Marchetti C. Long-term investigation of decompression as a definitive treatment for mandibular cysts associated with impacted third molars. *J Am Dent Assoc.* 2018;149(11):953-9.
23. Takagi S, Koyama S. Guided Eruption of an impacted second premolar associated with a dentigerous cyst in the maxillary sinus of a 6-year-old child. *J Oral Maxillofac Surg.* 1998;56(2):2379.
24. Buyukkurt MC, Omezli MM, Miloglu O. Dentigerous cyst associated with an ectopic tooth in the maxillary sinus: a report of 3 cases and review of the literature. *Oral Surg Oral Med Oral Pathol Oral Radiol.* 2010;109(1):67-71.
25. Girish G, Kumar M, Umashankar DN, Sharma R, Veeresh M, Bhandari A. Case report dentigerous cyst in maxillary sinus: A Rare Occurrence. *J Oral Maxillofac Pathol.* 2011;2(1):19-23.
26. Miyawaki S, Hyomoto M, Tsubouchi J, Kirita T, Sugimura M. Eruption speed and rate of angulation change of a cyst-associated mandibular second premolar after marsupialization of a dentigerous cyst. *Am J Orthod.* 1999;116(5):578-84.
27. Waly S. Marsupialization of a large pediatric mandibular cyst with a multipurpose space maintainer, a prospective study. *Egypt J Oral Maxillofac Surg.* 2019;10(4):118-22.
28. Meningaud JP, Oprean N, Pitak-Arnrop P, Bertrand JC. Odontogenic cysts: a clinical study of 695 cases. *J Appl Oral Sci.* 2006;48(2):59-62.
29. Weber AL, Kaneda T, Scrivani SJ, Aziz S. *Jaw: cysts, tumors, and nontumorous lesions. Head and neck imaging, 4th edn.* Mosby, St. Louis. 2003:930-94.
30. Kadam NS, De Ataide ID, Raghava P, Fernandes M, Hede R. Management of large radicular cyst by conservative surgical approach: a case report. *J Clin Diagnostic Res.* 2014;8(2):239-41.
31. Nakamura N, Mitsuyasu T, Mitsuyasu Y, Taketomi T, Higuchi Y, Ohishi M. Marsupialization for odontogenic keratocysts: long-term follow-up analysis of the effects and changes in growth characteristics. *Oral Surg Oral Med Oral Pathol Oral Radiol.* 2002;94(5):543-53.
32. Öztan MD. Endodontic treatment of teeth associated with a large periapical lesion. *Int Endod J.* 2002;35(1):73-8.
33. Neaverth EJ, Burg HA. Decompression of large periapical cystic lesions. *J Endod.* 1982;8(4):175-82.
34. Samuels HS. Marsupialization: Effective management of large maxillary cysts: report of a case. *Oral Surg Oral Med Oral Pathol Oral Radiol.* 1965;20(5):676-83.